

## CURRENT CONCEPTS REVIEW

# Patellar Instability

By Alexis Chiang Colvin, MD, and Robin V. West, MD

- Recurrent patellar instability can result from osseous abnormalities, such as patella alta, a distance of >20 mm between the tibial tubercle and the trochlear groove, and trochlear dysplasia, or it can result from soft-tissue abnormalities, such as a torn medial patellofemoral ligament or a weakened vastus medialis obliquus.
- Nonoperative treatment includes physical therapy, focusing on strengthening of the gluteal muscles and the vastus medialis obliquus, and patellar taping or bracing. Acute medial-sided repair may be indicated when there is an osteochondral fracture fragment or a retinacular injury.
- The recent literature does not support the use of an isolated lateral release for the treatment of patellar instability.
- A patient with recurrent instability, with or without trochlear dysplasia, who has a normal tibial tubercle-trochlear groove distance and a normal patellar height may be a candidate for a reconstruction of the medial patellofemoral ligament with autograft or allograft.
- Distal realignment procedures are used in patients who have an increased tibial tubercle-trochlear groove distance or patella alta. The degree of anteriorization, distalization, and/or medialization depends on associated arthrosis of the lateral patellar facet and the presence of patella alta. Associated medial or proximal patellar chondrosis is a contraindication to distal realignment because of the potential to overload tissues that have already undergone degeneration.

The incidence of primary patellar dislocation is 5.8 per 100,000, and this increases to twenty-nine per 100,000 in the ten to seventeen-year-old age group<sup>1,2</sup>. The recurrence rate ranges from 15% to 44% after nonoperative treatment of an acute injury<sup>2</sup>. If the patient experiences a subsequent patellar dislocation, there is a 50% chance of recurrent episodes<sup>1</sup>. Although the recurrence rate is relatively low after a primary patellar dislocation, many patients continue to have pain and mechanical symptoms after the initial dislocation episode<sup>3</sup>. Atkin et al. found that 58% (forty-three) of seventy-four patients continued to have limitation in strenuous activity at six months after the injury<sup>4</sup>. It has been reported that up to 55% of patients fail to return to sports activity after a primary patellar dislocation<sup>4</sup>.

Instability of the patellofemoral joint is a multifactorial problem. Patellar stability relies on the limb alignment, the osseous architecture of the patella and the trochlea, the integrity of the soft-tissue constraints, and the interplay of the sur-

rounding muscles. Treatment of patellar instability requires an understanding of these relationships and how to evaluate them.

### Anatomy

#### Joint Geometry

Patellofemoral joint stability is influenced by the geometry of the trochlear groove, including its depth and steepness. The trochlear groove has a sophisticated geometry with a complex shape that does not have a constant cross section along its length. The lateral facet of the trochlear groove is highest on the anterior aspect of the femur and decreases in height more distally and posteriorly, giving more osseous constraint to the patella in extension and early flexion. In contrast, the Q angle (the angle between the lines of action of the patella and the quadriceps tendon) is largest and the quadriceps and patellar tendon tension is lowest in extension. These two variables counteract the osseous constraint of the trochlea and contribute to greater patellar instability in extension and lower

**Disclosure:** The authors did not receive any outside funding or grants in support of their research for or preparation of this work. Neither they nor a member of their immediate families received payments or other benefits or a commitment or agreement to provide such benefits from a commercial entity. No commercial entity paid or directed, or agreed to pay or direct, any benefits to any research fund, foundation, division, center, clinical practice, or other charitable or nonprofit organization with which the authors, or a member of their immediate families, are affiliated or associated.

degrees of flexion. The quadriceps and patellar tendons provide a strong posterior force vector during knee flexion, contributing to increased patellar stability with knee flexion. As the knee flexes and extends, the contact area moves across the patella. The patella leaves its engagement with the groove as the knee reaches full extension. When the knee starts to bend, the initial contact is at the distal and lateral edge of the patellar articular surface, which does not extend to the inferior facet. As the patella moves distally with knee flexion, the contact area on the patella moves proximally. In deep knee flexion ( $120^\circ$ ), the medial facet, or so-called odd facet, contacts the lateral margin of the medial femoral condyle<sup>5</sup>.

Patella alta has been associated with recurrent dislocations<sup>6,7</sup>. Patella alta results in less osseous stability because the degree of flexion at which the patella engages in the trochlea is higher than that in a normal knee. Under normal conditions, the patella usually engages by  $20^\circ$  of flexion. Furthermore, knees with patella alta have reduced patellar contact areas when compared with knees with normal patellar height, and these reduced patellar contact areas lead to greater patellofemoral stress during fast walking<sup>8,9</sup>.

### Limb Alignment

Femoral and tibial torsion can play an important role in patellar instability. A more widely recognized aspect of osseous alignment is the Q angle. The Q angle is largest in full extension because the tibia rotates externally in terminal knee extension (the so-called screw-home mechanism), moving the tibial tuberosity more laterally<sup>10</sup>. Because the Q angle is greatest in full extension, this is the position in which the patella is at greatest risk for dislocation. In this position, the patella disengages from the trochlea and the posteriorly directed force from the extensor mechanism that holds the patella in the groove is the lowest.

The Q angle is difficult to measure because of the mobility of the patella. Quadriceps tension pulls the patella in a proximal-lateral direction in full extension. If the patella is unstable, it subluxates laterally, resulting in a falsely low Q-angle measurement. Therefore, it is important to keep the patella located in the trochlear groove manually during the measurement. Limb rotation should also be controlled during measurement since external tibial torsion can increase the apparent Q angle.

### Retinacula

The iliotibial band attaches to the Gerdy tubercle distally but also has attachments to the patellar and quadriceps tendons. It has been found that tension in the iliotibial band causes the patella to track in a more lateral position. There are three layers that make up the lateral side of the patellar attachments. The superficial layer is confluent with the iliotibial band. The intermediate layer is the lateral patellofemoral band, or the iliotibial patellar band. This band extends from the deep layer of the iliotibial band to the midlateral aspect of the patella. The deep layer is confluent with the knee capsule<sup>11</sup>.

The medial patellofemoral ligament is the primary passive soft-tissue restraint to lateral patellar displacement. It provides

50% to 60% of lateral restraint from  $0^\circ$  to  $30^\circ$  of knee flexion<sup>12</sup>. The medial patellofemoral ligament runs transversely from the proximal half of the medial patellar border to the femur near the medial epicondyle. The superficial fibers of the medial patellofemoral ligament pass over the saddle between the epicondyle and the adductor tubercle and insert 1.9 mm anterior and 3.8 mm distal to the adductor tubercle<sup>13</sup>. The medial patellofemoral ligament provides an important stabilizing force on the medial side of the knee. A study of cadavers showed that cutting the medial structures results in a 50% decrease in the force required to move the patella 10 mm laterally<sup>14</sup>.

### Muscles

The vastus medialis obliquus and vastus lateralis obliquus originate from septa alongside the femur and approach the patella from directions that deviate from the anatomic axis of the femur. These muscles can pull the patella medially or laterally. The vastus medialis obliquus has a mean orientation that deviates  $47^\circ \pm 5^\circ$  medially from the femoral axis, and the vastus lateralis obliquus has a mean orientation that deviates  $35^\circ \pm 4^\circ$  laterally from the axis<sup>15</sup>. An imbalance of strength may lead to instability. The vastus medialis obliquus is the first part of the quadriceps to weaken and the last to strengthen when function is inhibited<sup>16</sup>.

It has been shown that, if the muscle force vectors are added together in the coronal plane, their resultant force is almost exactly parallel to the femoral anatomic axis. If the force-producing capacity of each muscle head is in proportion to its physiologic cross-sectional area, the vastus medialis obliquus could contribute 10% of the total quadriceps tension<sup>15</sup>.

If the vastus medialis obliquus is completely relaxed, lateral patellar stability is reduced at all angles of knee flexion from  $0^\circ$  to  $90^\circ$ . Goh et al. found lateral stability to be reduced by 30% when the vastus medialis obliquus was relaxed at  $20^\circ$  of knee flexion<sup>17</sup> and that relaxation of the vastus medialis obliquus caused the patella to displace laterally 4 mm and also increased the load on the lateral facet<sup>17</sup>.

### Radiographic Evaluation

Standard radiographs for assessment of patellar instability include posteroanterior weight-bearing views of both knees in  $45^\circ$  of flexion, lateral views, and Merchant views. For the Merchant view, the knee is flexed  $45^\circ$  over the end of the table and the x-ray beam is inclined  $30^\circ$  downward<sup>18</sup>. This view is used to assess for patellar tilt, patellar sublaxation, and trochlear dysplasia. Patellar sublaxation is assessed by measuring the congruence angle, which reflects the relationship of the patellar articular ridge to the intercondylar sulcus and averages approximately  $6^\circ \pm 11^\circ$  in the medial direction<sup>18</sup>. The sulcus angle is formed by the highest points of the medial and lateral femoral condyles and the lowest point of the intercondylar sulcus and is approximately  $138^\circ \pm 6^\circ$ <sup>18</sup>. A sulcus angle of  $>145^\circ$  is indicative of trochlear dysplasia<sup>19</sup>. The lateral patellofemoral angle, as described by Laurin et al., is used to assess patellar tilt and is best evaluated on an axial radiograph of the patella with the knee flexed  $20^\circ$ <sup>20</sup>. Further flexion can result in a falsely normal angle<sup>20</sup>.

Patella alta can be assessed on lateral radiographs with use of the Blackburne-Peel ratio, which appears to rely less on the anatomy of the patella and the location of the tibial tubercle and more on consistent osseous landmarks; it has better interobserver reliability<sup>21,22</sup> than the Insall-Salvati ratio. Trochlear dysplasia is represented on a perfect lateral radiograph by the so-called crossing sign, a line represented by the deepest part of the trochlear groove crossing the anterior aspect of the condyles (Fig. 1)<sup>19</sup>. Other radiographic evidence of trochlear dysplasia on the lateral radiograph is the presence of a supratrochlear spur and a double contour representing a hypoplastic medial condyle. In a comparison of radiographs of 143 knees operated on for the treatment of patellar instability and 190 control radiographs, Dejour and Le Coultre found that 96% of patients with a history of a true patellar dislocation had evidence of trochlear dysplasia<sup>23</sup>. However, because of a lack of interobserver and intraobserver agreement<sup>24</sup>, the original system used to classify trochlear dysplasia was subsequently revised<sup>23</sup> (Fig. 2).

Cross-sectional imaging with transverse computed tomography slices at different positions along the lower limb can provide a three-dimensional view of the patellofemoral joint and be used to assess the lateral offset of the tibial tuberosity from the deepest point in the trochlear groove (Fig. 3). A distance between the tibial tuberosity and the trochlear groove exceeding 20 mm is nearly always associated with patellar instability<sup>19</sup>.

Magnetic resonance imaging is also useful for evaluating the medial-sided structures supporting the patella and identifying associated chondral injuries. When magnetic resonance imaging findings were correlated with operative findings, magnetic resonance imaging was found to be 85% sensitive and 70% accurate in detecting disruption of the medial patellofemoral ligament<sup>25</sup>. Typical injuries seen after a patellar dislocation include cartilage damage or bone bruising of the medial patellar facet and the lateral femoral condyle<sup>26</sup>. Injury to the vastus medialis obliquus, which lies superficial to the medial patellofemoral ligament, frequently presents as edema, hemorrhage, and/or elevation of the muscle away from the medial femoral condyle<sup>25,27</sup>. Approximately 50% to 80% of injured medial patellofemoral ligaments are disrupted at their femoral origin<sup>25,27,28</sup>.

### Nonoperative Treatment

To our knowledge, no studies have demonstrated the efficacy of physical therapy or bracing in the treatment of acute patellar dislocations. However, the aim of treatment after a patellar dislocation is to decrease swelling, promote vastus medialis obliquus and gluteal activity, and increase the range of motion of the knee. Swelling has a detrimental effect on quadriceps activity so the faster the swelling is reduced, the better the outcome for the patient. Few studies have addressed the nonoperative treatment of primary patellar dislocation<sup>29-34</sup>. Treatment regimens range from immediate mobilization without a brace to cast immobilization in extension for six weeks. Immobilization in extension may help the medial structures to heal, but stiffness may be a problem with this treatment. In a

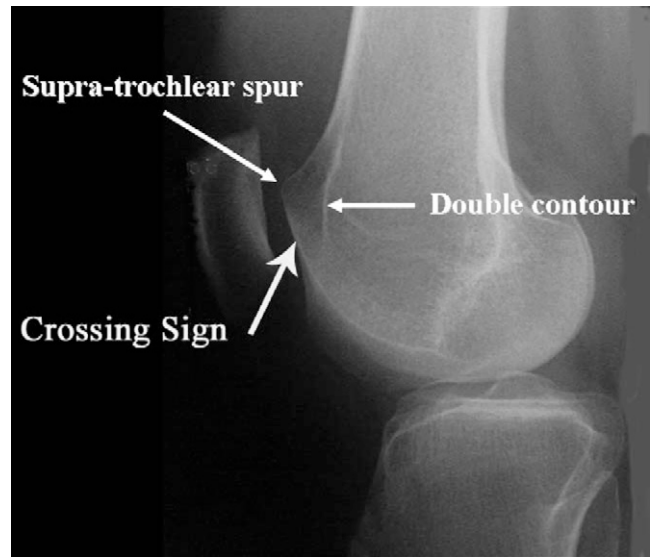


Fig. 1

Radiograph demonstrating findings of trochlear dysplasia, including the crossing sign, supratrochlear spur, and double contour (a hypoplastic medial facet). (Reprinted, with permission, from: Dejour D, Le Coultre B. Osteotomies in patello-femoral instabilities. *Sports Med Arthrosc*. 2007;15:40.)

study by Maenpaa and Lehto, 100 patients who had experienced a primary patellar dislocation were treated with one of three methods: cast immobilization, a posterior splint, or a patellar bandage or brace<sup>29</sup>. The cast and splint were worn for six weeks. Patients were followed for an average of thirteen years after the initial injury. There was a threefold higher risk of redislocation in patients treated with the patellar bandage or brace. The cast immobilization resulted in a higher rate of stiffness.

Patients with chronic patellar instability may benefit from physical therapy, which can help them to regain strength, motion, and proprioception. Patellar taping may help to control excessive patellar motion during therapy. Taping has also been shown to increase quadriceps muscle torque and to activate the vastus medialis obliquus earlier than the vastus lateralis during stair ascent and descent<sup>35,36</sup>.

Frequently, patients with chronic patellar instability have weak gluteal muscles. This weakness results in adduction and internal rotation of the femur during weight-bearing activities, which may accentuate the patellar instability. Strengthening the gluteal muscles or taping the hip to promote external rotation of the femur may help to address this problem.

There is increasing evidence that weight-bearing or closed-chain training is more efficacious than open-chain exercises. Stensdotter et al. found that closed-chain knee extension promoted simultaneous onset of electromyographic activity in the four different muscle portions of the quadriceps in asymptomatic subjects<sup>37</sup>. The rectus femoris had the earliest response while the vastus medialis obliquus had the latest response with lower amplitude in open-chain extension.

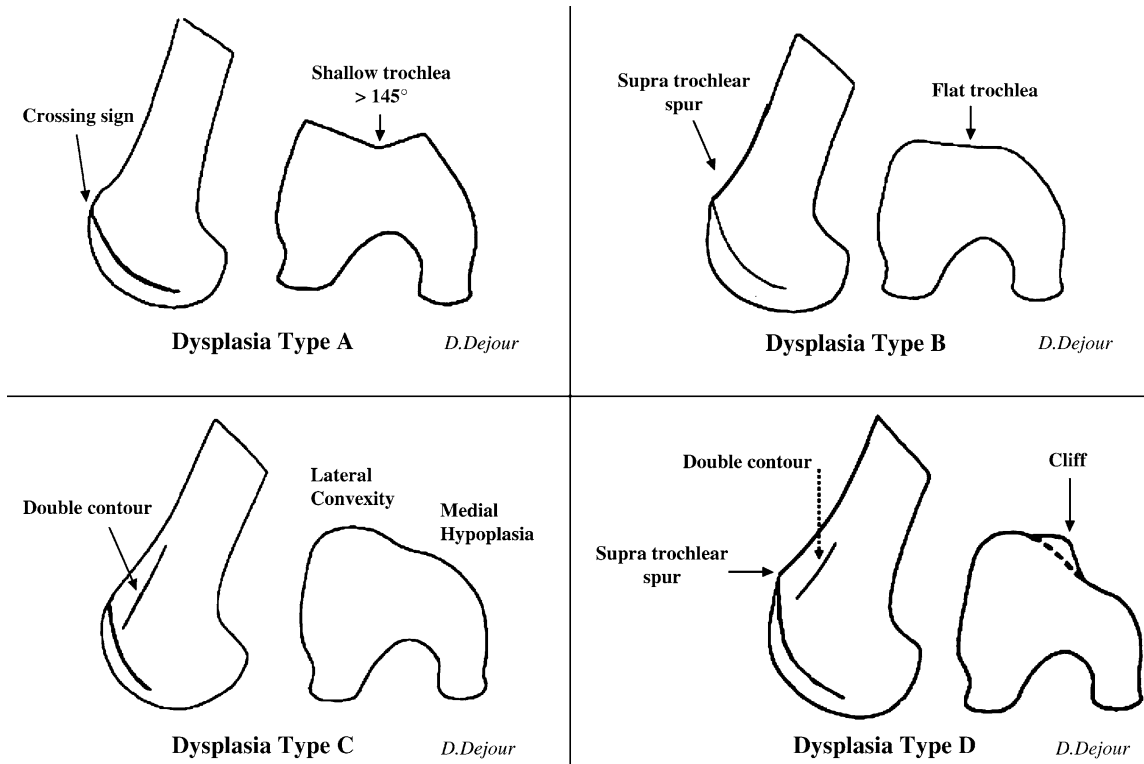


Fig. 2

Classification of trochlear dysplasia. Type A: crossing sign, with trochlear morphology preserved (fairly shallow trochlea [ $>145^\circ$ ]). Type B: crossing sign, supratrochlear spur, and flat or convex trochlea. Type C: crossing sign, with double contour. Type D: crossing sign, supratrochlear spur, double contour, asymmetry of trochlear facets, and vertical link between medial and lateral facets (cliff pattern). (Reprinted, with permission, from: Dejour D, Le Coultre B. Osteotomies in patello-femoral instabilities. *Sports Med Arthrosc.* 2007;15:40.)

Escamilla et al. also found that open-chain exercises promoted more rectus femoris activity and that closed-chain exercises produced more vastus activity<sup>38</sup>. Closed kinetic training allows training of the vastus muscles simultaneously with gluteal and trunk-muscle strengthening to control limb position.

### Operative Treatment

More than 100 different operations have been described for the treatment of patellar instability, and these procedures typically involve a combination of lateral release, medial imbrication, distal realignment, and anteromedialization of the tibial tubercle<sup>39</sup>. The so-called gold-standard treatment for patellar instability has yet to be defined. The literature reflects this in that no two studies have used the same operative procedure, inclusion and exclusion criteria, or outcome measures. Furthermore, there is a lack of prospective randomized trials.

#### Lateral Release

An isolated lateral release is the only procedure that has been shown to be ineffective for the treatment of patellar instability. While a lateral release can be useful in the treatment of lateral patellar compression syndrome, it does not yield acceptable results in patients with patellar instability<sup>40</sup>. In fact, all twenty-eight patients in one series who underwent lateral release for

patellar dislocation continued to experience dislocations<sup>40</sup>. Lattermann et al. reviewed the results from fourteen studies on lateral release for the treatment of patellar instability<sup>41</sup>. Although there was an average 80% patient-satisfaction rating in the short term, this rating had dropped to 63.5% after more than four years of follow-up<sup>41</sup>. The poor results after lateral release can be attributed to the inability of the procedure to align the patella more medially<sup>42</sup>. Furthermore, lateral release can be complicated by medial patellar instability if the release extends into, and detaches, the vastus lateralis obliquus<sup>41</sup>.

If the tibial tubercle-to-trochlear groove distance is  $<20$  mm and there are minimal medial patellofemoral degenerative changes, lateral release may be performed in combination with a medial-sided procedure such as a medial plication or a reconstruction of the medial patellofemoral ligament<sup>43</sup>. If there is osseous malalignment, these soft-tissue procedures can be combined with osseous procedures<sup>44</sup>.

#### Medial Repair

We are aware of only two prospective randomized trials comparing medial repair with nonoperative treatment of acute patellar dislocation. In studies of 127 patients with a first-time patellar dislocation followed for two<sup>30</sup> and seven<sup>31</sup> years, Nikku et al. found no significant difference between the results of

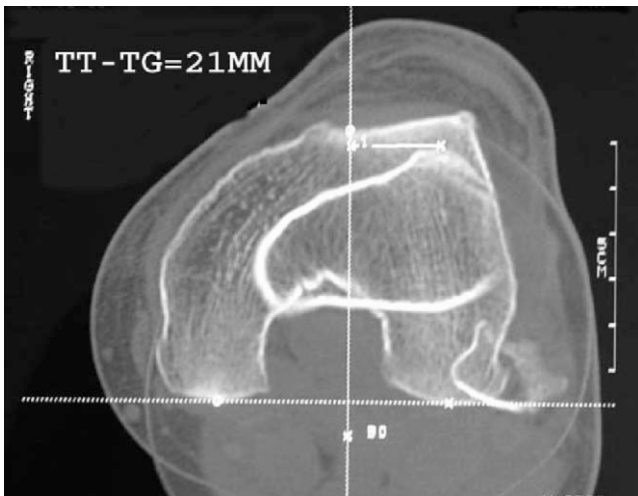


Fig. 3

The tibial tubercle-to-trochlear groove (TT-TG) distance is measured by superimposing axial computed tomography images of the tibial tubercle and the trochlear groove with the knee in extension. The normal distance ranges from 10 to 15 mm. (Reprinted, with permission, from: Dejour D, Le Coultre B. Osteotomies in patello-femoral instabilities. *Sports Med Arthrosc.* 2007;15:41.)

operative and nonoperative treatment with respect to scores determined with the systems of Kujala et al.<sup>45</sup> ( $p = 0.6$ ), Flandry et al.<sup>46</sup> ( $p = 0.1$ ), and Tegner and Lysholm<sup>47</sup> ( $p = 0.7$ ); they also found no difference in the rate of recurrence of subluxations or dislocations. Palmu et al. found that the rates of redislocation (approximately 70%) were similar in patients who had been treated with repair of the medial structures and those who had had nonoperative treatment<sup>34</sup>. At fourteen years, the two groups had similar good-to-excellent subjective outcome scores<sup>34</sup>. Both groups of authors concluded that there was no advantage to primary repair of the medial structures after a first-time dislocation. On the other hand, several authors have reported good or excellent functional outcome scores and few redislocations after arthroscopic medial plication for treatment of recurrent patellar instability<sup>48,49</sup>.

Acute medial-sided repair does have its proponents in clinical practice. In a recent survey of the National Football League Physician's Society (NFLPS), 6% (two) of thirty-one surgeons indicated that they would perform an early repair to treat an acute patellar dislocation without a loose body in a high-school, college, or professional athlete<sup>50</sup>. Early operative repair to treat an acute patellar dislocation without a loose body was not recommended for athletes at any level by 58% of the surgeons. Ahmad et al. repaired the medial patellofemoral ligament in addition to the vastus medialis obliquus, if it was torn, because of the importance of the vastus medialis obliquus as a dynamic medial stabilizer<sup>51</sup>, and there were no recurrent dislocations in their series.

Advocates for medial imbrication, as opposed to reconstruction of the medial patellofemoral ligament, cite the potential for overload of the patella with a graft reconstruction<sup>43</sup>. The native medial patellofemoral ligament has a load to failure

of 208 N<sup>52</sup>, and a hamstring graft used to reconstruct the medial patellofemoral ligament can generate up to 1600 N<sup>43</sup>. However, because medial imbrication is a nonanatomic procedure, it can result in excessive medialization of the patella or abnormal tracking. In a biomechanical study, Ostermeier et al. found that the combination of a lateral release and a medial imbrication tensioned with the knee at 45° resulted in significantly medialized ( $p < 0.01$ ) and internally tilted ( $p < 0.01$ ) patellar movement when compared with the intact knee condition<sup>53</sup>. Furthermore, medial imbrication fails to address problems with the medial patellofemoral ligament at the femoral attachment<sup>54</sup>.

### Reconstruction of the Medial Patellofemoral Ligament

Reconstruction of the medial patellofemoral ligament has the advantage of addressing damage at the adductor tubercle<sup>54</sup>. Comparing studies is difficult, as a review of the English-language literature identified only eight papers describing a variety of medial patellofemoral ligament reconstruction procedures and outcome scales<sup>55</sup>. There was no consensus with regard to the choice of graft, graft positioning, graft tension, or static versus dynamic reconstruction.

Adductor magnus autografts, semitendinosus autografts and allografts, and tibialis anterior allografts have all been proposed as possible graft choices<sup>53,56-61</sup>. Steiner et al. recommended the use of bone-quadriceps tendon autograft or bone-patellar tendon allograft for severely dysplastic knees in which more strength was thought to be warranted<sup>60</sup>. Farr and Schepesis advocated the use of a doubled semitendinosus allograft, not for its strength but rather to reproduce the broad attachment site on the patella<sup>57</sup>.

Use of a doubled hamstring tendon graft could be problematic if it is malpositioned, since it is stronger and stiffer than the native medial patellofemoral ligament<sup>62</sup>. Elias and Cosgarea performed a biomechanical study and found a significant increase in force on the medial patellar facet with either 5 mm of proximal malpositioning ( $p < 0.01$ ) or a graft that was 3 mm shorter than the native medial patellofemoral ligament ( $p < 0.01$ )<sup>61</sup>. Furthermore, a combination of the two errors led to a medial tilt moment from full extension through 90° of flexion. Increased pressures could theoretically lead to degeneration of the cartilage and arthrosis, while undertightening could lead to recurrent instability<sup>60</sup>. Thus, Elias and Cosgarea recommended placing the femoral attachment of the graft 1 cm distal to the adductor tubercle to avoid overloading the medial patellofemoral cartilage. A biomechanical study by Beck et al. demonstrated that, when  $>2$  N of tension was used to secure the reconstruction of the medial patellofemoral ligament, there was a significant increase in medial patellofemoral contact pressures ( $p < 0.05$ )<sup>62</sup>. There is also a risk of applying a net posteromedial force on the patella as the reconstruction results in a posterior force as well<sup>62</sup>.

The appropriate knee flexion angle at which to tension the graft is also controversial. While some believe the medial patellofemoral ligament to be isometric<sup>60,63</sup>, others have shown that it is not<sup>52,54</sup>. Tensioning the graft at between 60° and 90° of

flexion<sup>54,59,60</sup>, instead of at the lower flexion angles (30° to 45°) that have been recommended by other authors<sup>53,57</sup>, has been advocated to avoid overtightening of the graft and to ensure that the patella has engaged the trochlea. LeGrand et al. recommended applying tension at 45° to 60° of flexion and also checking that there is symmetric medial and lateral translation of the patella at 20° of flexion<sup>64</sup>. Farr and Schepsis described an “anatomometric” placement of the graft: tensioning the graft with the knee in 30° of flexion so that it becomes more lax with further flexion and tighter in terminal extension<sup>57</sup>.

A dynamic reconstruction of the medial patellofemoral ligament has been proposed as an alternative that is better than a static reconstruction. Ostermeier et al. performed a dynamic reconstruction by transferring the distal end of the semitendinosus behind the proximal aspect of the medial collateral ligament to the medial margin of the patella<sup>53</sup>. The authors found that a static reconstruction medialized the patella significantly more than the dynamic reconstruction did ( $p < 0.01$ ). Thus, a dynamic reconstruction could theoretically protect against overtensioning of the graft. Deie et al.<sup>56</sup> found that dynamic reconstruction provided a significant improvement ( $p < 0.0001$ ) in scores derived with the system of Kujala et al.<sup>45</sup>, with no recurrent dislocations in forty-six knees in forty-three patients followed for a mean of 9.5 years (range, five to twelve years).

However, Panagopoulos et al. believed that the medial collateral ligament is not an adequate pulley for the graft because its fibers are parallel to the direction of movement of the patella<sup>54</sup>. In their experience, use of the medial collateral ligament as a pulley led to splitting of the ligament during motion of the knee and loosening of the graft. They proposed using, instead, the medial intermuscular septum as a pulley for a semitendinosus autograft that has been detached at the myotendinous junction and pulling the graft through a bone tunnel in the patella<sup>54</sup>. In their series of twenty-five patients, there were improvements in the Tegner and Lysholm<sup>47</sup> and International Knee Documentation Committee (IKDC)<sup>65</sup> scores and no cases of redislocation at a mean of thirteen months postinjury.

The type of fixation of the medial patellofemoral ligament has also varied. Mountney et al. performed a biomechanical study comparing several different techniques, including suture repair, suture anchor repair, and allograft reconstruction with either blind-tunnel (ending in the medial femoral condyle) or through-tunnel (fixation in the lateral femoral condyle) fixation<sup>66</sup>. The strength of the reconstruction with the through-tunnel fixation ( $195 \pm 66$  N) was essentially the same as that of the intact medial patellofemoral ligament ( $208 \pm 90$  N) ( $p > 0.05$ ).

Fracture of the patella after fixation of the graft through a bone tunnel has been described<sup>54,58</sup>. In a study of twenty-four knees treated with reconstruction of the medial patellofemoral ligament, Mikashima et al. reported two patellar fractures, both of which occurred through bone tunnels in the patella<sup>58</sup>. The authors recommended suturing the graft to the patellar periosteum in all patients except those with a thin periosteum. However, we are not aware of any biomechanical studies comparing tunnel with suture-anchor fixation.

Reconstruction of the medial patellofemoral ligament has had good results in terms of preventing future subluxations or dislocations<sup>54,58,59</sup>. However, not all patients with recurrent patellar instability may benefit from this reconstruction. Nomura and Inoue evaluated twelve knees in twelve patients at an average of 4.2 years (range, 3.1 to 5.6 years) after reconstruction of the medial patellofemoral ligament<sup>59</sup>. Using the Insall scale, they found only fair results in patients with preexisting chondromalacia patella. Thus, they recommended reconstruction of the medial patellofemoral ligament for patients without advanced changes in the patellar cartilage.

Biomechanically, reconstruction of the medial patellofemoral ligament provides more stability than a medial tibial tubercle transfer does. Ostermeier et al. evaluated patellar kinematics in cadaver knees after either a medial transfer of the tibial tubercle or a reconstruction of the medial patellofemoral ligament with a semitendinosus autograft<sup>67</sup>. Patellar movement and strain in the medial patellofemoral ligament were measured with and without a 100-N lateral subluxation force under both testing conditions. While loading of the native medial patellofemoral ligament was greatest in full extension, the reconstruction of the medial patellofemoral ligament reduced the ligament load and lateral patellar displacement compared with those parameters after the medial transfer of the tibial tubercle, regardless of the knee flexion angle. On the basis of their results, the authors concluded that reconstruction of the medial patellofemoral ligament was better than medial transfer of the tibial tuberosity for stabilizing patellar movement under a laterally directed force. However, reconstruction of the medial patellofemoral ligament does not address potential osseous problems and can also result in overload of the medial patellofemoral cartilage<sup>60,61</sup>.

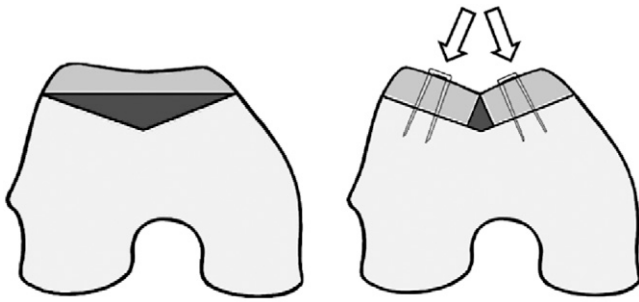
### Trochleoplasty

Trochleoplasty has been used with equivocal results, as reported in the European literature. Concerns about possible serious and irreversible articular and subchondral injury to the trochlea have limited its use in the United States.

Indications for a sulcus-deepening trochleoplasty include abnormal patellar tracking with a J-sign, usually manifested by a tibial tubercle-trochlear groove distance of greater than 10 to 20 mm<sup>23</sup>, and/or a dome-shaped trochlea noted on a perfect lateral radiograph with overlap of the posterior condyles in a patient with recurrent patellar instability<sup>68</sup>. In a trochleoplasty, cancellous bone is exposed in the trochlea by elevating a strip of cortical bone around the edge of the trochlea. The new trochlear sulcus is created proximal and 3° to 6° lateral to the previous sulcus by removing cancellous bone. The trochlear bone shell is then impacted into the new sulcus and fixed with two small staples (Fig. 4). The bone can also be secured with resorbable sutures<sup>69,70</sup>.

Verdonk et al. reported equivocal results at eighteen months (range, eight to thirty-four months) after trochleoplasty in thirteen knees in twelve patients<sup>71</sup>. Their indication for the operation was patellar pain with or without recurrent patellar instability. According to the Larsen-Lauridsen scoring





### Deepening Trochleoplasty (Dejour)

Fig. 4

To perform a trochleoplasty, a deeper sulcus is created by removing cancellous bone in the trochlear groove and repositioning the cortical bone. (Reprinted, with permission, from: Dejour D, Le Coultre B. Osteotomies in patello-femoral instabilities. *Sports Med Arthrosc.* 2007;15:44.)

system, which takes into account crepitus, range of motion, and stiffness, seven patients had a poor score. Because the authors included patients with patellar pain but no evidence of instability, their results are not comparable with those of other studies<sup>68-70,72,73</sup>. Although there were no postoperative patellar dislocations, postoperative arthrofibrosis was found in five of the thirteen knees.

Several investigators have reported improved subjective outcome scores in the short term after trochleoplasty<sup>68,69,72,73</sup>. Furthermore, there is an improvement in radiographic measurements, including a decrease in boss height or an increase in trochlear depth<sup>68,70</sup>. Preoperative degenerative changes of the patellar or trochlear articular cartilage have been associated with fair or poor results<sup>69,73</sup>. Like Verdonk et al.<sup>71</sup>, Donell et al. reported several cases that were complicated by postoperative arthrofibrosis<sup>68</sup>. Von Knoch et al. reported what we believe to be the largest study on trochleoplasty with the longest follow-up to date<sup>70</sup>. Trochleoplasty and medial reefing, with or without reconstruction of the medial patellofemoral ligament, was performed in forty-five knees in thirty-eight patients followed for a mean of 8.3 years (range, four to fourteen years). The most recent score, according to the system of Kujala et al.<sup>45</sup>, averaged 94.9 points (range, 80 to 100 points), but no preoperative scores were available for comparison. One patient had a positive apprehension test and subluxation postoperatively, but no patient had a postoperative patellar dislocation. The depth of the trochlea increased, and the trochlear boss height was reduced. Although the trochleoplasty was effective in preventing future patellar dislocations, it did not halt the progression of patellofemoral arthritis. In fact, at the time of the latest follow-up, ten knees had osteoarthritic changes in the patellofemoral compartment that were grade 2 or worse according to the system of Iwano et al.<sup>74</sup> and fifteen (43%) of thirty-five knees had worsening of preoperative patellofemoral pain.

Concerns about the viability of the articular cartilage after trochleoplasty were addressed in a study by Schottle et al.<sup>75</sup>. Two osteochondral biopsy specimens from each of

three patients under the age of twenty-one years were obtained at the time of a second arthroscopic procedure for the treatment of lateral patellofemoral adhesions at six, eight, and nine months after trochleoplasty. Using the International Cartilage Repair Society scale<sup>76</sup> to rate the cartilage, the authors found that tissue in the trochlear groove remained viable, with retention of distinctive hyaline architecture and composition and only a few minor changes in the calcified layers.

Trochleoplasty may not be the only option for patients with recurrent patellar instability and trochlear dysplasia. Steiner et al. reported the results of reconstruction of the medial patellofemoral ligament in patients with trochlear dysplasia<sup>60</sup>. There was a significant improvement in the scores derived with the systems of Kujala et al.<sup>45</sup>, Lysholm and Gillquist<sup>77</sup>, and Tegner and Lysholm<sup>47</sup> ( $p < 0.001$ ) and no recurrent dislocations at the time of the latest follow-up. Furthermore, there was no significant association between the severity of the dysplasia and the scores derived with the systems of Kujala et al. ( $p = 0.07$ ), Lysholm and Gillquist ( $p = 0.32$ ), and Tegner and Lysholm ( $p = 0.38$ ).

### Tibial Tubercle Transfer

Several types of distal realignment have been described for the treatment of patellar instability. A medial transfer of the tibial tubercle (an Elmslie-Trillat procedure)<sup>78</sup> and anteromedialization of the tibial tubercle<sup>79</sup> have both been successful in the treatment of patellar instability<sup>80-87</sup>. Anteromedial tibial tubercle transfer has had success as a treatment both for instability due to patellar malalignment and for pain due to distal or lateral articular damage<sup>42</sup>. When the tibial tubercle is transferred anteromedially, the patella engages earlier in flexion and offloads the damaged distal articular cartilage.

Biomechanically, overmedializing the tubercle (>15 mm past the original insertion site) can increase contact pressures in the medial patellar facet and medial compartment<sup>88</sup>. On the basis of these data, Kuroda et al. recommended avoiding overmedialization of the tibial tubercle in patients with a varus knee or degenerative changes of the medial compartment and in those who have had a medial meniscectomy<sup>88</sup>.

Nakagawa et al. performed an Elmslie-Trillat procedure in forty-five knees in thirty-nine patients for the treatment of recurrent dislocation of the patella<sup>82</sup>. They assessed their outcomes both at an average of forty-five months and at an average of 161 months. Although instability did not increase with time, there were six postoperative dislocations, two of which became recurrent in patients with ligamentous laxity. A longer length of time between the first dislocation and the operation was correlated with a poorer result. Degenerative changes noted on radiographs were also correlated with increased pain and worse clinical results. Ninety-one percent (forty-one) of the forty-five knees had a good or excellent Fulkerson score<sup>79</sup> at the time of the first follow-up; however, only 64% (twenty-nine) of the forty-five knees had a good or excellent score at the time of the final follow-up. Thus, Nakagawa et al. recommended performing the Elmslie-Trillat procedure before degenerative changes are seen in the patellofemoral joint.

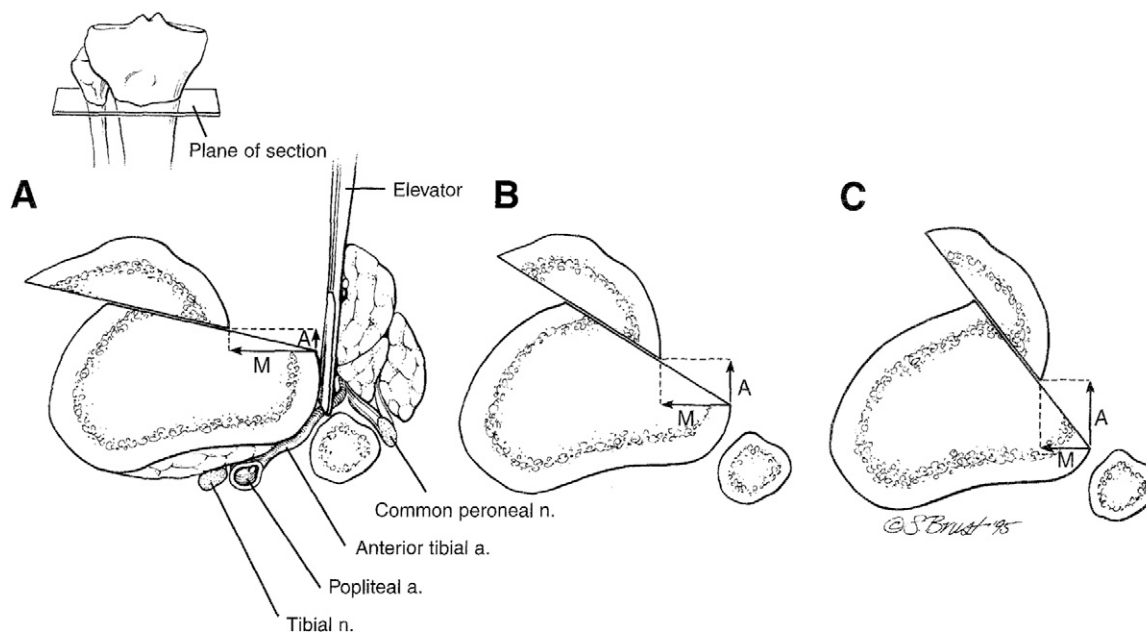


Fig. 5

Tibial tubercle realignment. A: A flat (no-angle) osteotomy allows medialization of the tibial tubercle. The elevator protects the neurovascular bundle. B: A steeper cut for equal anteriorization and medialization of the tibial tubercle. C: A very steep cut provides maximum anteriorization of the tibial tubercle with less medialization. (Reprinted, with permission, from: Buuck DA, Fulkerson JP. Anteromedialization of the tibial tubercle: a 4- to 12-year follow-up. *Op Tech Sports Med.* 2000;8:136-7.)

Carney et al. reviewed the results of the Elmslie-Trillat procedure for the treatment of recurrent subluxation and dislocation of the patella in fifteen knees in fourteen patients<sup>89</sup>. The authors compared the outcomes at a mean of three years with those at a mean of twenty-six years and found no difference in instability between the two time-periods. Although not significant, there was a trend toward a worsening Cox score<sup>90</sup> with time, which occurred even though the articular cartilage was grossly intact.

Koeter et al. reported the results of medial realignment of the tibial tubercle for patients with either painful lateral maltracking (with no instability) or patellar instability for longer than one year and a tibial tubercle-trochlear groove distance of >15 mm<sup>86</sup>. There was no difference in the distance of the medial displacement between the groups. A mean of 5.7 mm of distalization of the tibial tubercle was achieved in nine patients with lateral maltracking and twenty-two patients with patellar instability. At two years postoperatively, although the patients with patellar instability had more variable outcomes, both groups had improvement in all scores, with no significant difference noted between the groups. Thus, the authors advocated a medial transfer, with or without distalization, for patients with either patellar maltracking or patellar instability.

Diks et al. found that a tibial tubercle transfer provided better results for patients with patellar maltracking and no instability than for patients with isolated patellar instability<sup>83</sup>. Tibial tubercle transfer was performed in forty-three knees, twenty-seven with objective evidence of patellar instability and sixteen with a laterally tracking patella. The mean duration of follow-up

was thirty-seven months. The transfers in the patients with patellar instability were, overall, more effective in improving stability, doing so in 96% (twenty-six) of the twenty-seven patients, than they were in improving pain (63% of the patients). On the other hand, a higher percentage of patients (81%, thirteen of sixteen) with patellar maltracking had good pain relief.

Barber and McGarry advocated the use of the modified Elmslie-Trillat procedure for treatment of patellofemoral instability without evidence of arthritis<sup>87</sup>. These authors performed a medial translation of the tibial tubercle hinged on a distal periosteal flap along with an arthroscopic lateral retinacular release and medial capsular reefing for patients with at least three recurrent patellar dislocations or subluxations that had been resistant to a minimum of three months of physical therapy or bracing. Of thirty-five patients followed for a mean of ninety-eight months, 91% (thirty-two) had no additional subluxations or dislocations. Furthermore, there was improvement in the IKDC<sup>65</sup>, Fulkerson knee<sup>79</sup>, and Lysholm and Gillquist<sup>77</sup> scores.

Fulkerson et al. described anteromedialization of the tibial tubercle to address degenerative changes of the articular cartilage<sup>79</sup> (Fig. 5). In a cadaver model of this procedure, pressure was shown to be decreased on the lateral patellar facet at lower angles of flexion (up to 30°) whereas pressure was equalized between the medial and lateral patellar facets at greater angles of flexion<sup>85</sup>. There was slight superior migration of the contact area of the patellofemoral joint with distalization<sup>85</sup>. Cadaver studies have also demonstrated that anteromedialization decreases the contact pressures on the trochlear side overall, primarily on the



**TABLE I Grades of Recommendation for Summaries or Review of Orthopaedic Surgical Studies**

Grade	Description
A	Good evidence (Level-I studies with consistent findings) for or against recommending intervention.
B	Fair evidence (Level-II or III studies with consistent findings) for or against recommending intervention.
C	Poor-quality evidence (Level-IV or V studies with consistent findings) for or against recommending intervention.
I	There is insufficient or conflicting evidence not allowing a recommendation for or against intervention.

lateral and central areas of the trochlea<sup>88</sup>. However, pressures are elevated on the medial aspect of the trochlea and the proximal-medial aspect of the patella at all flexion angles, and thus caution should be used when performing an anteromedialization procedure in patients with medial-sided defects<sup>88</sup>.

Buuck and Fulkerson reviewed their results with anteromedialization at an average of 8.2 years postoperatively<sup>81</sup>. Their indications for the procedure were painful patellofemoral maltracking (subluxation or tilt) with degenerative changes on the distal and lateral aspects of the patella. Poorer results were associated with Outerbridge<sup>91</sup> grade-3 or 4 lesions in the central or medial aspects of the trochlea. Notably, three of the six fair or poor results were in patients who had compensation claims or were involved in litigation. Overall, 74% (thirty-one) of the forty-two patients had a good or excellent result at an average of 8.2 years postoperatively.

Pritsch et al. reported their results of tibial tubercle transfer for treatment of recurrent patellar instability, anterior knee pain, and evidence of maltracking on a dynamic computed tomography scan<sup>85</sup>. Sixty-nine knees followed for a median of 6.2 years had a significant improvement between the preoperative and postoperative Lysholm and Gillquist<sup>77</sup> and Karlsson<sup>92</sup> score categories of instability, pain, and stair-climbing ( $p < 0.001$ ). However, patients who had had only instability preoperatively did better than patients with pain or both pain and instability preoperatively. A better outcome was correlated with male sex, intact patellar articular cartilage, and symptoms of patellar instability. Physical examination findings that correlated with a

worse prognosis included a positive patellar grind test, retinacular pain, a positive patellar tilt test, and a positive J-sign. The duration of follow-up was also positively correlated with better Lysholm and Gillquist<sup>77</sup> and Karlsson<sup>92</sup> scores, which the authors attributed to the need for quadriceps recovery in the short term. Furthermore, there was no deterioration of the results with time.

Pidoriano et al. found that the location of articular cartilage damage in the patellofemoral joint correlated with the outcome after anteromedialization<sup>80</sup>. Of thirty-six patients (thirty-seven knees), 56% (twenty) had the procedure performed because of patellar instability. All twenty-three patients with distal and lateral patellar lesions were extremely satisfied with the result of the procedure. There was a 95% rate of good-to-excellent results (if no Workers' Compensation claim was involved), and 87% had good-to-excellent pain relief. The authors recommended not proceeding with the operation if medial, proximal, or diffuse lesions were present on the patella or if central lesions were present on the trochlea. Interestingly, the Outerbridge<sup>91</sup> classification of the lesion had no effect on the outcome.

Palmer et al. also reported satisfactory results after anteromedialization for treatment of both instability and painful patellar maltracking<sup>84</sup>. In a study of eighty-four patients followed for a mean of 5.6 years, the result was good to excellent in 80% of patients with dislocation and 71% of patients with pain from maltracking. There was no significant difference in outcome between the groups, leading the authors to recommend anteromedialization of the tibial tubercle with distalization as an effective procedure for both instability and pain due to maltracking. Predictors of poor postoperative results were postoperative anterior knee pain and a previous realignment procedure.

Fracture of the proximal part of the tibia or of the tibial tubercle after tibial tubercle transfer has been reported by several authors<sup>86,93,94</sup>. All cases occurred within three months after the operation and were attributed to early weight-bearing. Suggested preventive measures have included avoidance of step cuts<sup>86</sup>, an osteotomy of at least 5 cm in length and 0.75 cm in thickness to avoid fracture of the tuberosity<sup>86</sup>, protected weight-bearing over six to eight weeks in a hinged knee brace, and advancement to full weight-bearing once the osteotomy site is fully healed<sup>93-95</sup>.

### Overview

The evaluation and treatment of patellar instability continue to evolve. The importance of a thorough physical examination and an accurate diagnosis cannot be stressed enough. We typically

**TABLE II Grades of Recommendation for the Treatment of Acute Patellar Dislocation and Chronic Patellar Instability with Associated Factors**

Disorder	Treatment	Grade of Recommendation
Acute patellar dislocation	Early medial-sided repair or nonoperative treatment	A
Chronic patellar instability with associated factors		
Patella alta	Tibial tubercle realignment	C
Medial patellofemoral ligament injury	Medial patellofemoral ligament reconstruction	C
Trochlear dysplasia	Trochleoplasty	C
Elevated tibial tubercle-to-trochlear groove distance	Tibial tubercle realignment	C

recommend nonoperative treatment with patellar bracing and therapy for primary patellar dislocations. We aspirate the effusion acutely to allow the patient to regain quadriceps strength and control. However, if a patient has a loose body after a dislocation, we recommend arthroscopy for removal or possibly fixation of the fracture fragment, in which case a medial repair will usually be performed simultaneously. When there is an extensive medial-sided injury, such as a femoral avulsion of the medial patellofemoral ligament in association with an extensive retinacular injury or avulsion of the vastus medialis obliquus, repair is usually recommended as well.

When physical therapy and bracing have failed, the surgical options should be tailored to the underlying pathological condition. The literature provides little support for the performance of an isolated lateral release for the treatment of patellar instability. Recurrent patellar instability can be addressed with either a reconstruction of the medial patellofemoral ligament or a distal patellar realignment. Reconstruction of the medial patellofemoral ligament can be performed in patients with recurrent instability, with or without trochlear dysplasia, who have a normal tibial tubercle-trochlear groove distance and a normal patellar height. Distal realignment procedures can be used in patients who have an increased tibial tubercle-trochlear groove distance or patella alta. A standard medialization of the tibial tubercle can be performed if there is a normal patellar height and trochlear

anatomy and an increased tibial tubercle-trochlear groove distance. Distalization of the tubercle can be added if there is concomitant patella alta, and anteromedialization of the tubercle is performed if there is lateral and/or distal patellar facet chondrosis. To avoid overloading the patella, a tubercle osteotomy should not be performed if there is associated medial or proximal patellar chondrosis.

While there is good evidence (Table I) for the nonoperative treatment of an acute patellar dislocation, most of the current surgical treatments for chronic patellar instability are based on Level-IV evidence (Table II). Prospective randomized trials are necessary to determine the optimal surgical treatment for chronic patellar instability. ■

Alexis Chiang Colvin, MD  
Mount Sinai School of Medicine, 5 East 98th Street,  
Box 1188, New York, NY 10029.  
E-mail address: alexis.colvin@gmail.com

Robin V. West, MD  
Center for Sports Medicine,  
University of Pittsburgh Medical Center,  
3200 South Water Street, Pittsburgh, PA 15203.  
E-mail address: westrv@upmc.edu

## References

- Fithian DC, Paxton EW, Stone ML, Silva P, Davis DK, Elias DA, White LM. Epidemiology and natural history of acute patellar dislocation. *Am J Sports Med.* 2004;32:1114-21.
- Hawkins RJ, Bell RH, Anisette G. Acute patellar dislocations. The natural history. *Am J Sports Med.* 1986;14:117-20.
- Cofield RH, Bryan RS. Acute dislocation of the patella: results of conservative treatment. *J Trauma.* 1977;17:526-31.
- Atkin DM, Fithian DC, Marangi KS, Stone ML, Dobson BE, Mendelsohn C. Characteristics of patients with primary acute lateral patellar dislocation and their recovery within the first 6 months of injury. *Am J Sports Med.* 2000;28:472-9.
- Goodfellow J, Hungerford DS, Zindel M. Patello-femoral joint mechanics and pathology. 1. Functional anatomy of the patello-femoral joint. *J Bone Joint Surg Br.* 1976;58:287-90.
- Insall J, Goldberg V, Salvati E. Recurrent dislocation and the high-riding patella. *Clin Orthop Relat Res.* 1972;88:67-9.
- Kannus PA. Long patellar tendon: radiographic sign of patellofemoral pain syndrome—a prospective study. *Radiology.* 1992;185:859-63.
- Ward SR, Powers CM. The influence of patella alta on patellofemoral joint stress during normal and fast walking. *Clin Biomech (Bristol, Avon).* 2004;19:1040-7.
- Ward SR, Terk MR, Powers CM. Patella alta: association with patellofemoral alignment and changes in contact area during weight-bearing. *J Bone Joint Surg Am.* 2007;89:1749-55.
- Hallén LG, Lindahl O. The "screw-home" movement in the knee-joint. *Acta Orthop Scand.* 1966;37:97-106.
- Terry GC, Hughston JC, Norwood LA. The anatomy of the iliopatellar band and iliotibial tract. *Am J Sports Med.* 1986;14:39-45.
- Desio SM, Burks RT, Bachus KN. Soft tissue restraints to lateral patellar translation in the human knee. *Am J Sports Med.* 1998;26:59-65.
- LaPrade RF, Engebretsen AH, Ly TV, Johansen S, Wentorf FA, Engebretsen L. The anatomy of the medial part of the knee. *J Bone Joint Surg Am.* 2007;89:2000-10.
- Senavongse W, Amis AA. The effects of articular, retinacular, or muscular deficiencies on patellofemoral joint stability. *J Bone Joint Surg Br.* 2005;87:577-82.
- Farahmand F, Senavongse W, Amis AA. Quantitative study of the quadriceps muscles and trochlear groove geometry related to instability of the patellofemoral joint. *J Orthop Res.* 1998;16:136-43.
- Stokes M, Young A. Investigations of quadriceps inhibition: implications for clinical practice. *Physiotherapy.* 1984;70:425-8.
- Goh JC, Lee PY, Bose K. A cadaver study of the function of the oblique part of vastus medialis. *J Bone Joint Surg Br.* 1995;77:225-31.
- Merchant AC, Mercer RL, Jacobsen RH, Cool CR. Roentgenographic analysis of patellofemoral congruence. *J Bone Joint Surg Am.* 1974;56:1391-6.
- Dejour H, Walch G, Nove-Josserand L, Guier C. Factors of patellar instability: an anatomic radiographic study. *Knee Surg Sports Traumatol Arthrosc.* 1994;2:19-26.
- Laurin CA, Dussault R, Levesque HP. The tangential x-ray investigation of the patellofemoral joint: x-ray technique, diagnostic criteria and their interpretation. *Clin Orthop Relat Res.* 1979;144:16-26.
- Seil R, Muller B, Georg T, Kohn D, Rupp S. Reliability and interobserver variability in radiological patellar height ratios. *Knee Surg Sports Traumatol Arthrosc.* 2000;8:231-6.
- Berg EE, Mason SL, Lucas MJ. Patellar height ratios. A comparison of four measurement methods. *Am J Sports Med.* 1996;24:218-21.
- Dejour D, Le Coultre B. Osteotomies in patello-femoral instabilities. *Sports Med Arthrosc.* 2007;15:39-46.
- Remy F, Chantelot C, Fontaine C, Demondion X, Migaud H, Gougeon F. Inter- and intraobserver reproducibility in radiographic diagnosis and classification of femoral trochlear dysplasia. *Surg Radiol Anat.* 1998;20:285-9.
- Sanders TG, Morrison WB, Singleton BA, Miller MD, Cornum KG. Medial patellofemoral ligament injury following acute transient dislocation of the patella: MR findings with surgical correlation in 14 patients. *J Comput Assist Tomogr.* 2001;25:957-62.
- Kirsch MD, Fitzgerald SW, Friedman H, Rogers LF. Transient lateral patellar dislocation: diagnosis with MR imaging. *AJR Am J Roentgenol.* 1993;161:109-13.
- Elias DA, White LM, Fithian DC. Acute lateral patellar dislocation at MR imaging: injury patterns of medial patellar soft-tissue restraints and osteochondral injuries of the inferomedial patella. *Radiology.* 2002;225:736-43.

28. Nomura E, Horiuchi Y, Inoue M. Correlation of MR imaging findings and open exploration of medial patellofemoral ligament injuries in acute patellar dislocations. *Knee*. 2002;9:139-43.
29. Maenpaa H, Lehto MU. Patellar dislocation. The long-term results of nonoperative management in 100 patients. *Am J Sports Med*. 1997;25:213-7.
30. Nikku R, Nietosvaara Y, Kallio PE, Aalto K, Michelsson JE. Operative versus closed treatment of primary dislocation of the patella. Similar 2-year results in 125 randomized patients. *Acta Orthop Scand*. 1997;68:419-23.
31. Nikku R, Nietosvaara Y, Aalto K, Kallio PE. Operative treatment of primarily patellar dislocation does not improve medium-term outcome: a 7-year follow-up report and risk analysis of 127 randomized patients. *Acta Orthop*. 2005;76:699-704.
32. Christiansen SE, Lind M, Maul M, Hansen MS, Lund B, Jakobsen BW. Repair of the medial patellofemoral ligament in primary dislocation of the patella: a prospective randomized study. Presented at the Sixth Biennial Congress of the International Society of Arthroscopy, Knee Surgery, and Orthopaedic Sports Medicine; 2007 May 27-31; Florence, Italy.
33. Stefancin JJ, Parker RD. First-time traumatic patellar dislocation: a systematic review. *Clin Orthop Relat Res*. 2007;455:93-101.
34. Palmu S, Kallio PE, Donell ST, Helenius I, Nietosvaara Y. Acute patellar dislocation in children and adolescents: a randomized clinical trial. *J Bone Joint Surg Am*. 2008;90:463-70.
35. Cowan SM, Bennell KL, Hodges PW. Therapeutic patellar taping changes the timing of vasti muscle activation in people with patellofemoral pain syndrome. *Clin J Sport Med*. 2002;12:339-47.
36. McConnell J. Rehabilitation and nonoperative treatment of patellar instability. *Sports Med Arthrosc*. 2007;15:95-104.
37. Stensdotter AK, Hodges PW, Mellor R, Sundelin G, Häger-Ross C. Quadriceps activation in closed and in open kinetic chain exercise. *Med Sci Sports Exerc*. 2003;35:2043-7.
38. Escamilla RF, Fleisig GS, Zheng N, Barrentine SW, Wilk KE, Andrews JR. Biomechanics of the knee during closed kinetic chain and open kinetic chain exercises. *Med Sci Sports Exerc*. 1998;30:556-69.
39. Vahasarja V, Kinnunen P, Lanning P, Serlo W. Operative realignment of patellar malalignment in children. *J Pediatr Orthop*. 1995;15:281-5.
40. Kolowich PA, Paulos LE, Rosenberg TD, Farnsworth S. Lateral release of the patella: indications and contraindications. *Am J Sports Med*. 1990;18:359-65.
41. Lattermann C, Toth J, Bach BR Jr. The role of lateral retinacular release in the treatment of patellar instability. *Sports Med Arthrosc*. 2007;15:57-60.
42. Fulkerson JP. Diagnosis and treatment of patients with patellofemoral pain. *Am J Sports Med*. 2002;30:447-56.
43. Tom A, Fulkerson JP. Restoration of native medial patellofemoral ligament support after patella dislocation. *Sports Med Arthrosc*. 2007;15:68-71.
44. Mulford JS, Wakeley CJ, Eldridge JD. Assessment and management of chronic patellofemoral instability. *J Bone Joint Surg Br*. 2007;89:709-16.
45. Kujala UM, Jaakkola LH, Koskinen SK, Taimela S, Hume M, Nelimarkka O. Scoring of patellofemoral disorders. *Arthroscopy*. 1993;9:159-63.
46. Flandry F, Hunt JP, Terry GC, Hughston JC. Analysis of subjective knee complaints using visual analog scales. *Am J Sports Med*. 1991;19:112-8.
47. Tegner Y, Lysholm J. Rating systems in the evaluation of knee ligament injuries. *Clin Orthop Relat Res*. 1985;198:43-9.
48. Nam EK, Karzel RP. Mini-open medial reefing and arthroscopic lateral release for the treatment of recurrent patellar dislocation: a medium-term follow-up. *Am J Sports Med*. 2005;33:220-30.
49. Ali S, Bhatti A. Arthroscopic proximal realignment of the patella for recurrent instability: report of a new surgical technique with 1 to 7 years of follow-up. *Arthroscopy*. 2007;23:305-11.
50. West RV. NFL Physician's Society Survey. Unpublished data; 2008.
51. Ahmad CS, Stein BE, Matuz D, Henry JH. Immediate surgical repair of the medial patellar stabilizers for acute patellar dislocation. A review of eight cases. *Am J Sports Med*. 2000;28:804-10.
52. Amis AA, Firer P, Mountney J, Senavongse W, Thomas NP. Anatomy and biomechanics of the medial patellofemoral ligament. *Knee*. 2003;10:215-20. Erratum in: *Knee*. 2004;11:73.
53. Ostermeier S, Holst M, Bohnsack M, Hurschler C, Stukenborg-Colsman C, Wirth CJ. In vitro measurement of patellar kinematics following reconstruction of the medial patellofemoral ligament. *Knee Surg Sports Traumatol Arthrosc*. 2007;15:276-85.
54. Panagopoulos A, van Niekerk L, Triantafillopoulos IK. MPFL reconstruction for recurrent patella dislocation: a new surgical technique and review of the literature. *Int J Sports Med*. 2008;29:359-65.
55. Smith TO, Walker J, Russell N. Outcomes of medial patellofemoral ligament reconstruction for patellar instability: a systematic review. *Knee Surg Sports Traumatol Arthrosc*. 2007;15:1301-14.
56. Deie M, Ochi M, Sumen Y, Adachi N, Kobayashi K, Yasumoto M. A long-term follow-up study after medial patellofemoral ligament reconstruction using the transferred semitendinosus tendon for patellar dislocation. *Knee Surg Sports Traumatol Arthrosc*. 2005;13:522-8.
57. Farr J, Schepsis AA. Reconstruction of the medial patellofemoral ligament for recurrent patellar instability. *J Knee Surg*. 2006;19:307-16.
58. Mikashima Y, Kimura M, Kobayashi Y, Miyawaki M, Tomatsu T. Clinical results of isolated reconstruction of the medial patellofemoral ligament for recurrent dislocation and subluxation of the patella. *Acta Orthop Belg*. 2006;72:65-71.
59. Nomura E, Inoue M. Hybrid medial patellofemoral ligament reconstruction using the semitendinosus tendon for recurrent patellar dislocation: minimum 3 years' follow-up. *Arthroscopy*. 2006;22:787-93.
60. Steiner TM, Torga-Spak R, Teitge RA. Medial patellofemoral ligament reconstruction in patients with lateral patellar instability and trochlear dysplasia. *Am J Sports Med*. 2006;34:1254-61.
61. Elias JJ, Cosgarea AJ. Technical errors during medial patellofemoral ligament reconstruction could overload medial patellofemoral cartilage: a computational analysis. *Am J Sports Med*. 2006;34:1478-85.
62. Beck P, Brown NA, Greis PE, Burks RT. Patellofemoral contact pressures and lateral patellar translation after medial patellofemoral ligament reconstruction. *Am J Sports Med*. 2007;35:1557-63.
63. Steensen RN, Dopirak RM, McDonald WG 3rd. The anatomy and isometry of the medial patellofemoral ligament: implications for reconstruction. *Am J Sports Med*. 2004;32:1509-13.
64. LeGrand AB, Greis PE, Dobbs RE, Burks RT. MPFL reconstruction. *Sports Med Arthrosc*. 2007;15:72-7.
65. Hefti F, Muller W, Jakob RP, Staubli HU. Evaluation of knee ligament injuries with the IKDC form. *Knee Surg Sports Traumatol Arthrosc*. 1993;1:226-34.
66. Mountney J, Senavongse W, Amis AA, Thomas NP. Tensile strength of the medial patellofemoral ligament before and after repair or reconstruction. *J Bone Joint Surg Br*. 2005;87:36-40.
67. Ostermeier S, Stukenborg-Colsman C, Hurschler C, Wirth CJ. In vitro investigation of the effect of medial patellofemoral ligament reconstruction and medial tibial tuberosity transfer on lateral patellar stability. *Arthroscopy*. 2006;22:308-19.
68. Donell ST, Joseph G, Hing CB, Marshall TJ. Modified Dejour trochleoplasty for severe dysplasia: operative technique and early clinical results. *Knee*. 2006;13:266-73.
69. Schottle PB, Fucentese SF, Pfirrmann C, Bereiter H, Romero J. Trochleoplasty for patellar instability due to trochlear dysplasia: a minimum 2-year clinical and radiological follow-up of 19 knees. *Acta Orthopaedica*. 2005;75:693-8.
70. von Knoch F, Bohm T, Burgi ML, von Knoch M, Bereiter H. Trochleoplasty for recurrent patellar dislocation in association with trochlear dysplasia. A 4- to 14-year follow-up study. *J Bone Joint Surg Br*. 2006;88:1331-5.
71. Verdonk R, Jansegers E, Stuyts B. Trochleoplasty in dysplastic knee trochlea. *Knee Surg Sports Traumatol Arthrosc*. 2005;13:529-33.
72. Koeter S, Pakvis D, van Loon CJ, van Kampen A. Trochlear osteotomy for patellar instability: satisfactory minimum 2-year results in patients with dysplasia of the trochlea. *Knee Surg Sports Traumatol Arthrosc*. 2007;15:228-32.
73. Utting MR, Mulford JS, Eldridge JD. A prospective evaluation of trochleoplasty for the treatment of patellofemoral dislocation and instability. *J Bone Joint Surg Br*. 2008;90:180-5.
74. Iwano T, Kurosawa H, Tokuyama H, Hoshikawa Y. Roentgenographic and clinical findings of patellofemoral osteoarthritis. With special reference to its relationship to femorotibial osteoarthritis and etiologic factors. *Clin Orthop Relat Res*. 1990;252:190-7.
75. Schottle PB, Schell H, Duda G, Weiler A. Cartilage viability after trochleoplasty. *Knee Surg Sports Traumatol Arthrosc*. 2007;15:161-7.
76. Mainil-Varlet P, Aigner T, Brittberg M, Bullough P, Hollander A, Hunziker E, Kandel R, Nehrer S, Pritzker K, Roberts S, Stauffer E; International Cartilage Repair Society. Histological assessment of cartilage repair: a report of the Histology

Endpoint Committee of the International Cartilage Repair Society (ICRS). *J Bone Joint Surg Am.* 2003;85(Suppl 2):45-57.

**77.** Lysholm J, Gillquist J. Evaluation of knee ligament surgery results with special emphasis on use of a scoring scale. *Am J Sports Med.* 1982;10:150-4.

**78.** Trillat A, Dejour H, Couette A. [Diagnosis and treatment of recurrent dislocations of the patella]. *Rev Chir Orthop Reparatrice Appar Mot.* 1964;50:813-24. French

**79.** Fulkerson JP, Becker GJ, Meaney JA, Miranda M, Folcik MA. Anteromedial tibial tubercle transfer without bone graft. *Am J Sports Med.* 1990;18:490-7.

**80.** Pidoriato AJ, Weinstein RN, Buuck DA, Fulkerson JP. Correlation of patellar articular lesions with results from anteromedial tibial tubercle transfer. *Am J Sports Med.* 1997;25:533-7.

**81.** Buuck DA, Fulkerson JP. Anteromedialization of the tibial tubercle: a 4- to 12-year follow-up. *Op Tech Sports Med.* 2000;8:131-7.

**82.** Nakagawa K, Wada Y, Minamide M, Tsuchiya A, Moriya H. Deterioration of long-term clinical results after the Elmslie-Trillat procedure for dislocation of the patella. *J Bone Joint Surg Br.* 2002;84:861-4.

**83.** Diks MJ, Wymenga AB, Anderson PG. Patients with lateral tracking patella have better pain relief following CT-guided tibial tuberosity transfer than patients with unstable patella. *Knee Surg Sports Traumatol Arthrosc.* 2003;11:384-8.

**84.** Palmer SH, Servant CT, Maguire J, Machan S, Parish EN, Cross MJ. Surgical reconstruction of severe patellofemoral maltracking. *Clin Orthop Relat Res.* 2004;419:144-8.

**85.** Pritsch T, Haim A, Arbel R, Snir N, Shasha N, Dekel S. Tailored tibial tubercle transfer for patellofemoral malalignment: analysis of clinical outcomes. *Knee Surg Sports Traumatol Arthrosc.* 2007;15:994-1002.

**86.** Koeter S, Diks MJ, Anderson PG, Wymenga AB. A modified tibial tubercle osteotomy for patellar maltracking: results at two years. *J Bone Joint Surg Br.* 2007;89:180-5.

**87.** Barber FA, McGarry JE. Elmslie-Trillat procedure for the treatment of recurrent patellar instability. *Arthroscopy.* 2008;24:77-81.

**88.** Kuroda R, Kambic H, Valdevit A, Andrich JT. Articular cartilage contact pressure after tibial tuberosity transfer. A cadaveric study. *Am J Sports Med.* 2001;29:403-9.

**89.** Carney JR, Mologne TS, Muldoon M, Cox JS. Long-term evaluation of the Roux-Elmslie-Trillat procedure for patellar instability: a 26-year follow-up. *Am J Sports Med.* 2005;33:1220-3.

**90.** Cox JS. An evaluation of the Elmslie-Trillat procedure for management of patellar dislocations and subluxations: a preliminary report. *Am J Sports Med.* 1976;4:72-7.

**91.** Outerbridge RE. The etiology of chondromalacia patellae. *J Bone Joint Surg Br.* 1961;43:752-7.

**92.** Karlsson J, Thomee R, Sward L. Eleven year follow-up of patello-femoral pain syndrome. *Clin J Sport Med.* 1996;6:22-6.

**93.** Stetson WB, Friedman MJ, Fulkerson JP, Cheng M, Buuck D. Fracture of the proximal tibia with immediate weightbearing after a Fulkerson osteotomy. *Am J Sports Med.* 1997;25:570-4.

**94.** Bellemans J, Cauwenberghs F, Brys P, Victor J, Fabry G. Fracture of the proximal tibia after Fulkerson anteromedial tibial tubercle transfer. A report of four cases. *Am J Sports Med.* 1998;26:300-2.

**95.** Cosgarea AJ, Schatzke MD, Seth AK, Litsky AS. Biomechanical analysis of flat and oblique tibial tubercle osteotomy for recurrent patellar instability. *Am J Sports Med.* 1999;27:507-12.