

## Patellofemoral Chondrosis

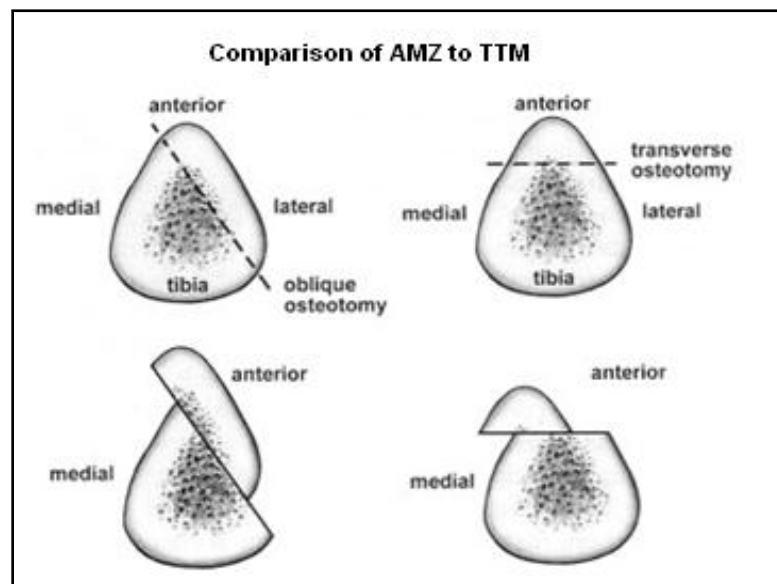
- **What is PF chondrosis?**

PF chondrosis (cartilage deterioration) is the softening or loss of smooth cartilage, most frequently that which covers the back of the kneecap, but the surgeon must also consider the cartilage condition of the entire knee. After a doctor determines PF chondrosis, the following information will be recorded:

- Grade (depth) of involvement (note areas worse than ICRS Grade 2)
- Area of involvement in millimeters
- Regions (locations) of involvement (important when shifting loads and contact area)
- Containment (condition and presence of the cartilage surrounding the lesion)

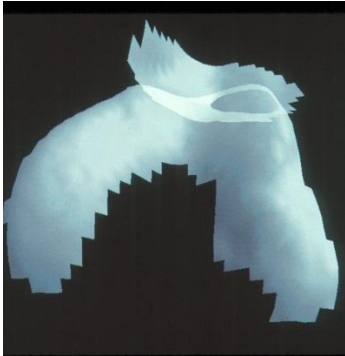
- **Can surgery help with PF chondrosis?**

If chondrosis, or deficient cartilage covering the sensitive underlying bone (cartilage has no nerves to cause direct pain) is the likely cause of pain, standard cartilage repair and restoration options can be applied ONLY if any abnormal force or contact areas are optimized by surgical procedures such as tibial tuberosity anterization (TTA or Maquet procedure), tibial tuberosity medialization (TTM or Elmslie-Trillat procedure), anteromedialization (AMZ or Fulkerson procedure). Releasing tight retinaculum or contractures around the patella is sometimes necessary with these procedures.



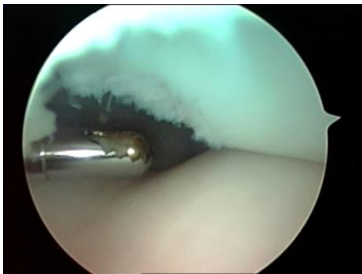If you have pain from a patella that is worn laterally with good cartilage medially, a tibial tubercle transfer alone may be the best option. The following stereophotogrammetric

picture demonstrates a patella that is chronically overloaded laterally. Anteromedial or medial tibial tubercle transfer alone will usually eliminate pain in such patients by transferring load off of a painful overloaded area onto healthy cartilage permanently:



Some patients have excruciating pain when stepping down with the opposite leg. This may signal that there is a softened area (chondrosis) at the lower end of the patella.

In this situation, a tibial tubercle anteriorization or anteromedialization will unload the painful, overloaded area and thereby eliminate the pain. The following picture demonstrates a **localized distal patella articular lesion** that, when chronically painful, may be unloaded by a tibial tubercle anteriorizing procedure, thereby eliminating the cause of chronic pain when all other non-surgical and arthroscopic options have been tried without success:



### What is PF pain and instability?

Pain and instability means that you feel pain in the PF compartment, and your patella or kneecap is unstable. Generally patients that fit into this group have pain which persists even after the pain of an instability episode resolves. Often this pain is caused by cartilage injury exposing sensitive bone under the damaged area. Combinations of tibial tubercle transfer, releasing contracture, ligament reconstruction and a cartilage restoration procedure may be needed in the treatment of some patients with complex PF pain and instability.

- **What is cartilage repair/restoration?**

Cartilage repair/restoration is an option at the patellofemoral compartment. **Cartilage repair/restoration should NEVER be applied to the PF compartment without first identifying all causes of pain and treating these.** When PF cartilage problems are beyond treatment with cartilage restoration, but the remainder of the knee joint is in good condition, patellofemoral arthroplasty also known as or total knee replacement (with metal and plastic components) may be necessary.

### **What surgical techniques can be used for cartilage repair?**

The following cartilage repair/restoration techniques can be used in the PF compartment and should be examined as options prior to considering patellofemoral arthroplasty:

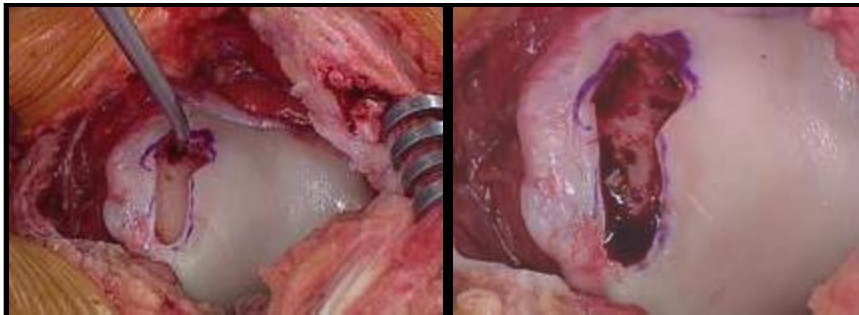
1. Marrow Stimulation/Microfracture
2. Osteochondral Autograft
3. Cultured Chondrocyte Applications
4. Osteochondral Allograft Transplantation

#### **1. Marrow Stimulation/ Microfracture**

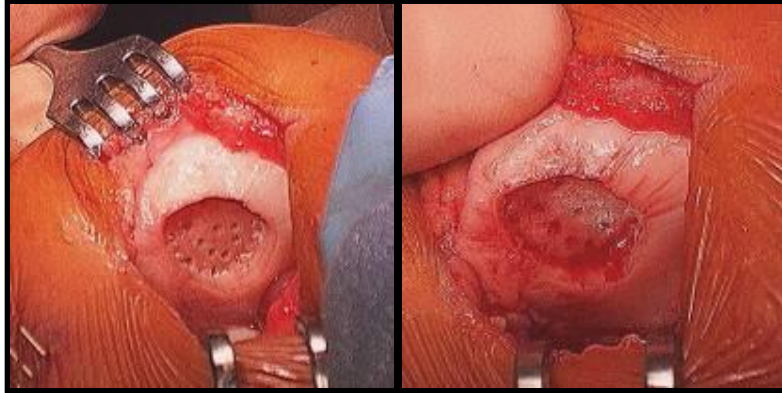
Microfracture surgery is a procedure where tiny fractures or lesions are surgically made in the underlying bone. In some cases the fractures are difficult to place arthroscopically and a surgeon made need to use an approach called a mini open approach. Once the microfracture is placed the release of pluripotent mesenchymal stem cells from the bone marrow occurs. This bone marrow stimulating technique may heal or repair the cartilage depending on the age of the individual, the size and localization of the cartilage defect, and the postoperative rehabilitation.

**NOTE** Less optimal results have been reported at the patella, and there is little data on the use for both the patella and trochlea.

#### **OPEN MICROFRACTURE OF THE TROCHLEA**



#### **OPEN MICROFRACTURE OF THE PATELLA**

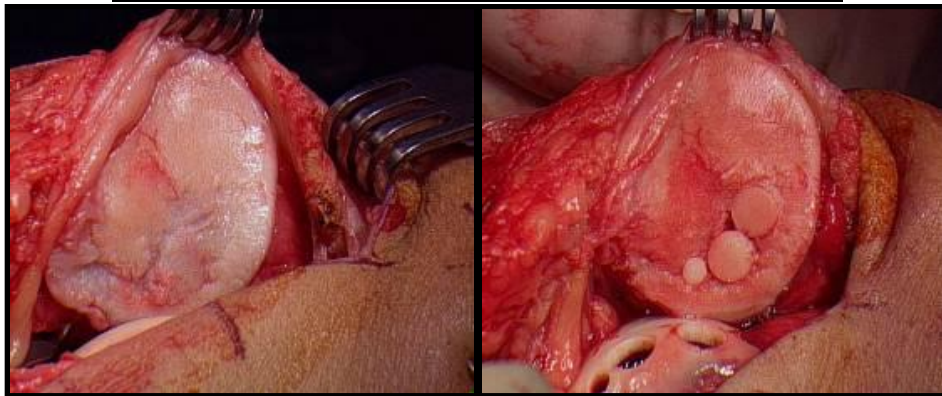


## 2. Osteochondral Autograft

Osteochondral autografting is a procedure where plugs of cartilage and bone are taken from a non-essential area of a knee and then transplanted to a weight bearing or damaged area. The bone of the plugs heals to the bone of the femur, and the cap of cartilage on each of these plugs forms a new cartilage surface.

**NOTE** Surgeons must consider the following when performing this procedure: which drill technique is best, difference in donor/recipient cartilage thickness, and difficult access to patella often requires a “mini” open technique.

### **OSTEOCHONDRAL AUTOGRAFT PLUGS TO PATELLA**

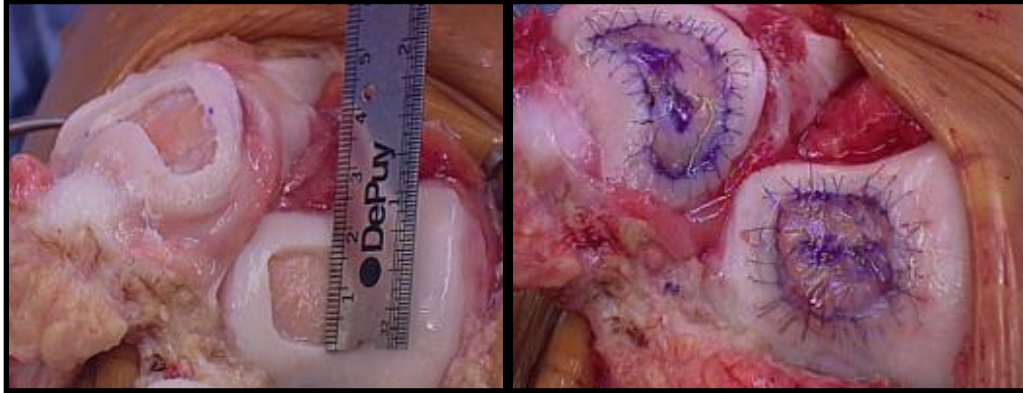


## 3. Cultured Chondrocyte Applications

A cultured chondrocyte application is a procedure where a surgeon performs an arthroscopic biopsy of a joint margin and harvests cells which become the source of the cultured chondrocytes. The live cells are sent to a laboratory and placed into a culture medium where they are multiplied using a cell-culture technique. Once the cells are ready they are sent back to the surgeon and then implanted (placed) in the damaged part of the knee. After implantation, the chondrocytes help form new, healthy cartilage.

**NOTE** When performing this procedure, a surgeon must match the facet (surface) curvature, and appreciate the depth of cartilage walls for proper placement of cultured chondrocytes.

**PATELLA AND TROCHLEA TREATED WITH CULTURED CHONDROCYTES INJECTED UNDER PATCH**




**4. Osteochondral Allograft Transplantation**

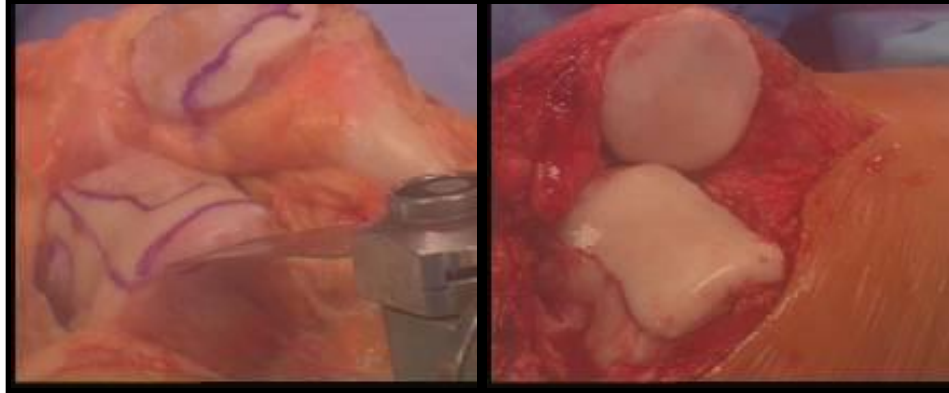
Osteochondral allografting is a cartilage transplantation procedure that is designed to reconstruct damage or diseased regions of the joint. The tissue is transplanted fresh, very similar to solid organ transplants; however, no tissue type matching is performed. The allograft generally does not evoke an immune response and is considered modestly immunogenic. The donor allograft is matched with the recipient based on the size needed, to ensure optimum fit of the allograft. Once a donor is available and matched to the recipient the individual is scheduled for surgery generally within 48-72 hours.

**NOTE** Bipolar outcomes are highly variable with this type of transplant.

**PATELLAR OSTEOCHONDRAL ALLOGRAFT PLUG TRANSPLANT**



**OSTEOCHONDRAL SHELL ALLOGRAFT REPLACING BOTH PATELLA AND TROCHLEA**



When none of these cartilage restoration procedures are likely to be successful, partial or total knee replacement may be necessary, or even patellectomy (removal of the patella) in rare instances.

### **PF Replacement Surgery**

Removal of the cartilage surfaces of the PF becomes necessary when joint preservation methods such as rest, weight loss, physical therapy, activity modification, anti-inflammatory medication, arthroscopic treatment, release or removal of painful tissue anteromedialization of the tibial tubercle for lateral PF arthritis, cartilage replacement/restoration, and alternative treatments are either not appropriate or have failed. In other words, replacement of the joint is the last alternative.

Joint replacement means that your PF joint is removed and replaced with metal and high density plastic. These components will wear over time and can loosen, particularly with vigorous activity. For this reason, replacement surgery is more desirable in older and less active patients. Nonetheless, PF replacement can be appropriate in some younger patients when no other option is available to restore improved function, and results of PF replacement are usually very good in the hands of a skilled joint replacement surgeon.

When other parts of your knee are arthritic also, a total knee replacement may be the best option. Again, this is generally most appropriate in older, somewhat less active patients.

### **What surgery is right for me?**

Only you and your surgeon can answer this question. PF pain is very common but it has several factors you must consider before deciding which surgery is best. Your surgeon will take these

factors into consideration and answer any questions you may have prior to surgery. Be sure you understand risks as well as benefits. None of the treatments noted are effective 100% of the time. You should obtain second opinions until you are comfortable, and be sure to exhaust non operative measures.

The images in this document were supplied by: Jack Farr, MD, Ron Hoekem, MD, and Tony Schepsis, MD.